

SOME HISTOLOGICAL STUDY OF THE LUNGS IN WHITE-EARED BULBUL (*PYCNONOTUS LEUCOTIS*)

Salim Salih Ali Al-Khakani, Siraj M. Al-Kafagy*, Ekhlas Abid Hamza Alalwany, Jaafar Ghazi,
Dheaa A. Neamah, Marwah Najeh Hammood and Zahraa Ali Al-Rubaie

Department of Anatomy and Histology, College of Veterinary Medicine, University of AL-Qasim Green, Babylon, Iraq.

*e-mail : drsirajmoner@vet.uoqasim.edu.iq

(Received 7 April 2021, Revised 6 July 2021, Accepted 15 July 2021)

ABSTRACT : Twelve of adult bulbul were used in this study, all birds were anesthetized by using chloroform inhalation, then the necropsy were applied to remove the lungs. All histological processing were occur then the histological slides were stained by Hematoxylin and Eosin stain. Microscopic examinations of the lungs in bulbul explained that the building units are parabronchi and numbers of atrial openings, the epithelia of parabronchi consist of cuboidal cells under lining layer of connective tissue and smooth muscles, the units opened into atria which pass to air capillaries through ducts designate infundibula, the simple squamous cells and layer of connective tissue shroud air capillaries, infundibula and atria (from internal to external), while the smooth muscles existent in atrial openings only. The interparabronchial connective tissue (interparabronchial septa) is separated between parabronchi, the arteries and veins passing via lung, the barrier to gas exchange formed from basement membrane only which detach between endothelium and epithelium.

Key words : White-eared, lung, respiratory system, bulbul.

How to cite : Salim Salih Ali Al-Khakani, Siraj M. Al-Kafagy, Ekhlas Abid Hamza Alalwany, Jaafar Ghazi, Dheaa A. Neamah, Marwah Najeh Hammood and Zahraa Ali Al-Rubaie (2021) Some histological study of the lungs in white-eared bulbul (*Pycnonotus leucotis*). *Biochem. Cell. Arch.* **21**, 4963-4965. DocID: https://connectjournals.com/03896.2021.21.4963

INTRODUCTION

The bird's respiratory tract composed of vascularized part (bronchial lungs) as union between air and blood and nonvascularized air sacs (Rastogi, 2007). The lung was surrounded by a thin colorless membrane and appear small in size in yellow-vented bulbul (*Pycnonotus goavier*) (Salim Salih, 2015). The thermo-regulation in birds by respiratory system, also sense of smell (Pesek, 2000). The avian respiratory system described as non-tidal (Suthers, 2004).

The parabronchi represent center of the pulmonary lobules which encapsulated by connective tissue, secondary bronchi are bifurcation of which and meet each other (McLelland, 1990; Getty, 1975; Dellman and Earell, 1998). Ostrich's lungs without connective tissue (septa) (Maina and Nathanel, 2001). Histologically parabronchial built From the inside out by epithelium (cuboidal or squamous) with loss secretory cells, light layer of collagen and elastic fibers layer and bundles of smooth muscle cells (no cartilages) (Aughey and Frye, 2001; Nganpiep and Maina, 2002; Wideman *et al*, 2004), the parabronchus leads into atrium (cavities) like air

vesicle padded by epithelia (squamous to cuboidal) the same lining the air capillaries, the septa separated between atrium (interatrial septa) and bundles of smooth muscle fibers surround arterial openings, in birds (Swenson, 2004; Maina and West, 2005; Reece, 2005; Samuelson, 2007).

The unite of gas exchange in avian represent meshwork between blood-carrying and air-filled capillaries (Baumel *et al*, 1993; West *et al*, 2009). The atrial veins which sign up nearby parabronchial lumen pulls up blood from capillaries exchange tissue of periparabronchial (Frandsen and Wilke, 2009), the least boundary to gas exchange in domestic fowl is blood-carrying and air-filled capillaries respectively (Rastogi, 2007; Frandsen and Wilke, 2009).

MATERIALS AND METHODS

Twelve of adult bulbul (regardless of the sex of the birds) are used in this study, all birds were collected from the sale of birds, the birds are transferred to the laboratory experimental birds were anesthetized by using chloroform inhalation in closed chambers and then the necropsy were

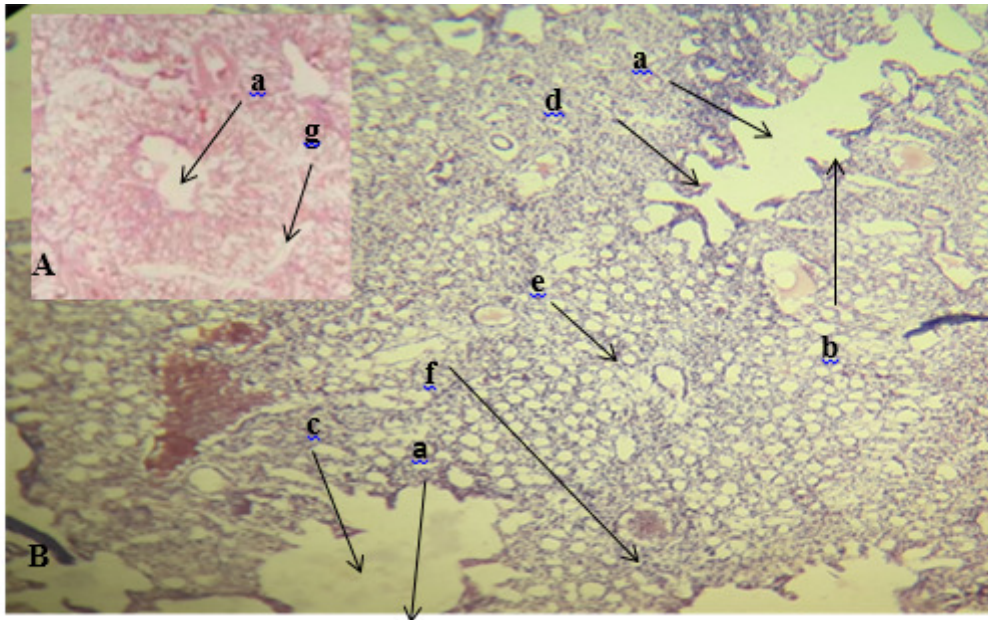


Fig. 1 : A and B Cross section of parabronchial in lung of bulbul demonstrate the parabronchi (a), atrial opening (smooth muscle fibers) (b), atria (c), infundibula (d), air capillaries (e), interparabronchial blood vessels (f), interparabronchial septa g, H & E stain X 10.




Fig. 2 : Cross section demonstrate the parabronchi (a), atrial opening with smooth muscle fibers (b), atria (c), infundibula (d), air capillaries (e) H & E stain X 40.

applied to remove the lung. All histological processing were occur then the histological slides were stained by Hematoxylin and Eosin stain (Luna, 1968).

RESULTS

Microscopic examinations of the lungs in bulbul explained that the building units are parabronchi which lead in to numbers of atrial opinings, the parabronchi histologically formed from epithelium layer consist of cuboidal cells under lining layer of connective tissu and

amnsular layer of smooth muscles (Fig. 1 A and B), the units opened into the many numbers dilated chambers called atria which pass to air capillaries through the small dilated ducts designate infundibula (Fig. 2) the simple squamous cells and layer of connective tissue shroud air capillaries, infundibula and atria(from internal to external), while the smooth muscles existent in atrial openings only.

The air capillaies are location of gas exchange (Fig. 1B), the interparabronchial connective tissue

(interparabronchial septa) is separated between parabronchi (Fig. 1 A) the arteries and veins passing via lung, the barrier to gas exchange formed from basement membrane only which detach between endothelium and epithelium.

DISCUSSION

The building units of lung in white eared bulbul (*Pycnonotus leucotis*) are parabronchi that confirmed with McLelland (1990), Getty (1975), Dellman and Earell (1998), who showed the bulk units of avian lung are the parabronchi, the parabronchi are opened into the many numbers dilated chambers called atria also this results are similar with Swenson (2004), Maina and West (2005), Reece (2005), Samuelson (2007) in chicken, turkey, duck and quail and in this birds the parabronchi are pierced by numerous openings which pass to air capillaries through the small dilated ducts designate infundibula the air capillaries as the site of exchange oxygen and carbon dioxide, which represent bronchi branches, the interparabronchial connective tissue (interparabronchial septa) is found in lungs of bulbul, the arteries and veins passing through the tissue of lung this results are accordance with Swenson (2004), Maina and West (2005), Reece (2005) and Samuelson (2007) in chicken, turkey, duck and quail (*Coturnix coturnix*), but un accordance with Maina and Nathanel (2001) demonstrated the interparabronchial septa are absent in lungs of ostrich.

The parabronchi composed from internal to external from one layer of squamous cells, stratum of connective tissue and thick layer of smooth muscle fibers our results are agreed with Aughey and Frye (2001), Nganpiep and Maina (2002), Wideman *et al* (2004) in chicken, turkey duck and quail, while the air capillaries, infundibula and atria were wrapped inside by two layers, simple squamous cells and connective tissue only and the smooth muscles existent in atrial openings only (Swenson, 2004; Maina and West, 2005; Reece, 2005; Samuelson, 2007) note the same results in chicken, turkey duck and quail.

The barrier to gas exchange in lungs of bulbul are formed from basement membrane only which separated between epithelium air capillaries epithelium and blood capillaries blood endothelium that harmonized with Frandson and Wilke (2009) in domestic fowl.

CONCLUSION

The histological structures of lung in white eared bulbul (*Pycnonotus leucotis*) are similar to the birds like in chicken, turkey, duck and quail.

REFERENCES

- Aughey E and Frye F L (2001) Avian respiratory system. In: *Comparative Veterinary Histology with Clinical Correlates*. Manson Ltd. Lon. pp. 93-94.
- Baumel J J, King A S, Breazile J E, Evans H E and Vandan Berge J C (1993) Respiratory system. In: *Hand book of Avian Anatomy Nomina Anatomica Avium*. 2nd (Ed): Club. Cambridge, Massachusetts. Pp. 257-299.
- Dellmann H D and Eurell J A (1998) Avian respiratory system. In: *Veterinary Histology*. Fifth (ed). William & Wilkins USA. pp. 162-164.
- Frandson R D, Wilke W L and Fails A D (2009) Poultry respiratory system. In: *Anatomy and Physiology of farm Animals*. 7th (ed). Wiley-Black Well. Pp. 471- 474.
- Getty R (1975) Aves respiratory system. In: *Anatomy of domestic animals*. W.S. Saunders Co. Philadelphia. pp. 1884-1917.
- Luna L G (1968) *Manual of histologic staining methods of 5th armed forces institute of pathology*. 3rd McGraw-Hill book Company- New York.
- Maina J N and Nathanel C (2001) Aqualitative and quantitative study of the lung of an ostrich, *Struthio Camelus*. *J. Exp. Biol.* **204**, 2313–2330.
- Maina J N and West J B (2005) Thin and Strong! TheBioengineering Dilemma in the Structural and Functional Design of the Blood-Gas Barrier. *Physiol. Rev.* **85**, 811-844 (Abstract).
- McLelland J (1990) Respiratory system. In: *A Colour Atlas of Avian Anatomy*. Wolfe Ltd. Eng. Pp. 95-119.
- Nganpiep L N and Maina J N (2002) Composite cellular defense stratagem in the avian respiratory system: functional morphology of the free (surface) macrophages and specialized pulmonary epithelia. *J. Anat.* **200**, 499–516
- Pesek L (2000) The avian respiratory system. *Pet Bird Magazine* 1-3.
- Rastogi S C (2007) Essential of animal physiology. *New Age Inter* pp. 263-285.
- Reece W O (2005) Avian respiratory system morphology. In: *Function Anatomy and Physiology of Domestic Animals*. 3rd (Ed): Lippincott Williams and Wilking. pp. 230-268.
- Salim Salih A Al-Ghakany (2015) Anatomical study of the primary bronchi and the lung in yellow – vented bulbul (*Pycnonotus goavier*). *Int. J. Adv. Res.* pp 818-822.
- Samuelson D A (2007) Avian respiratory system. In: *Text book of Veterinary Histology*. Saunders Elsevier. Pp. 246-248.
- Suthers R A (2004) Vocal mechanisms in birds and bats: a comparative view. *Ann. Brazilian Acad. Sci.* **76**(2), 247-252.
- Swenson M J (2004) *Ducks physiology of domestic animals*. 9th (Ed): Darya Ganj, New Delhi. Pp. 203.
- West J B, Watson R R and Fu Z (2009) Major differences in the pulmonary circulation between birds and mammals. *Respir. Physiol. Neurobiol.* **157**(2-3), 382–390.
- Wideman R F, Chapman M E, Wang W and Erf G F (2004) Immune Modulation of the Pulmonary Hypertensive Response to Bacterial lipopolysaccharide (Endotoxin) in broilers. *Poul. Sci. Assoc.* **83**, 624–637.